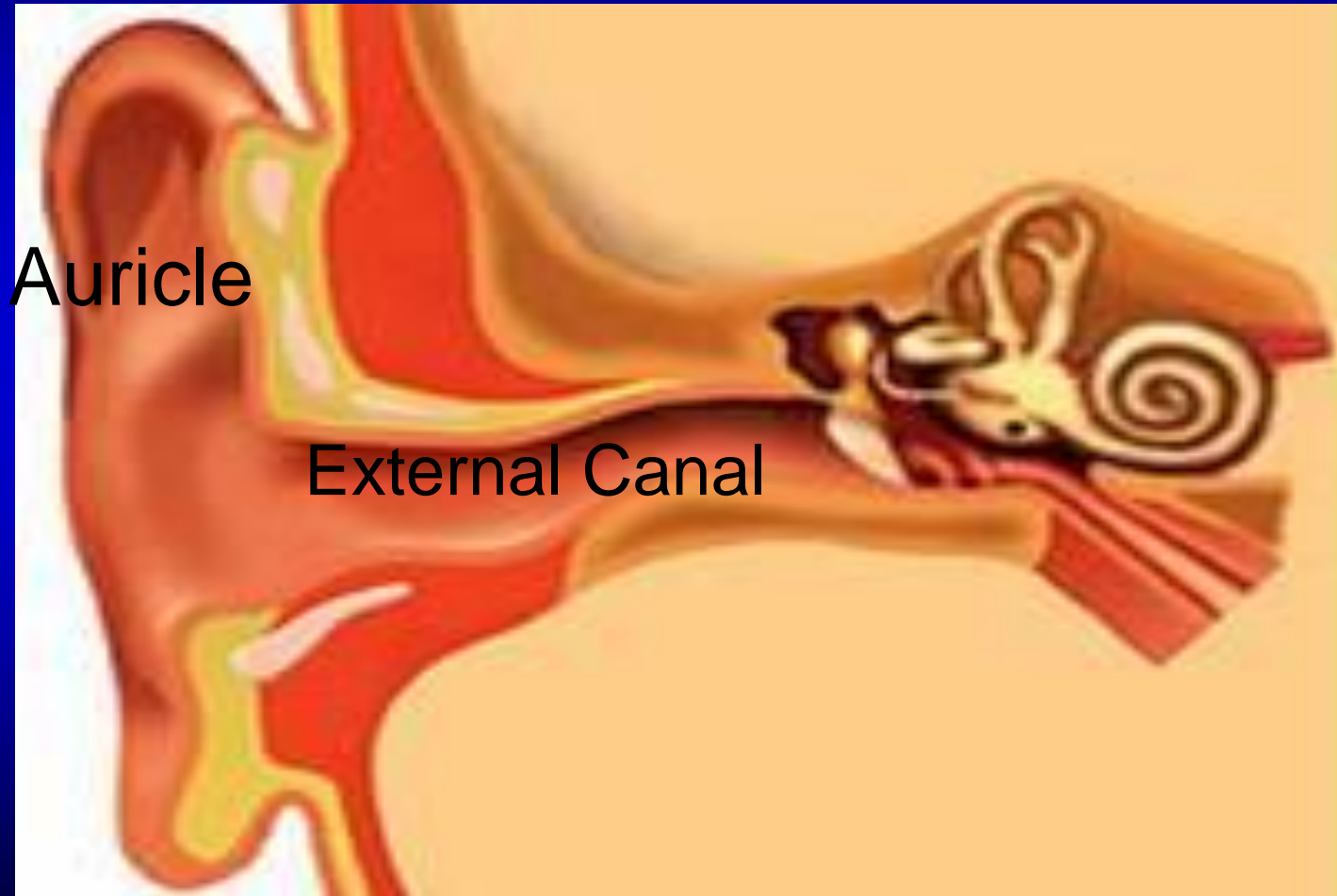


# Anatomy of the ear

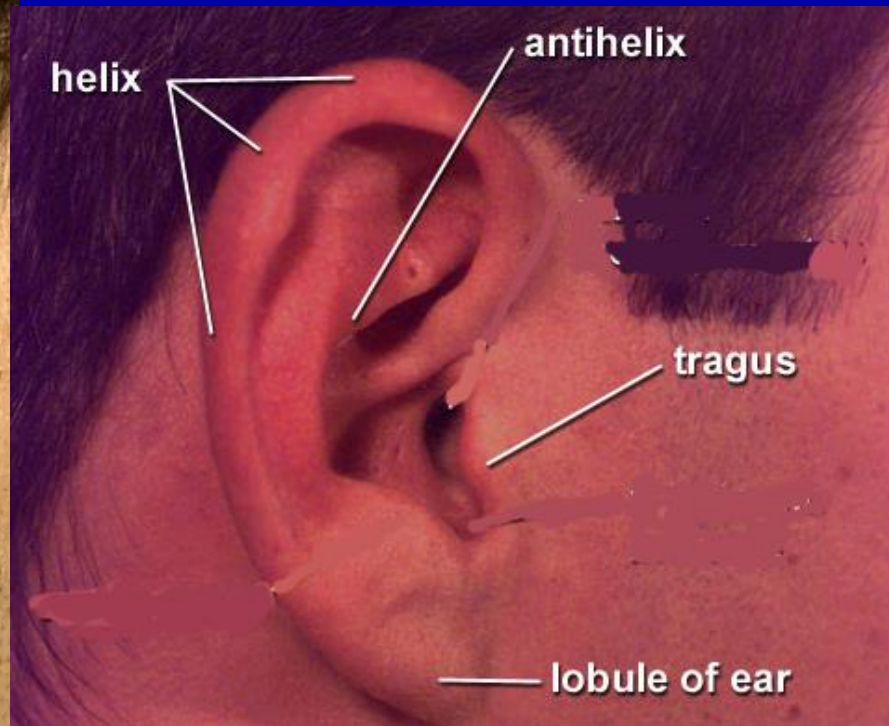
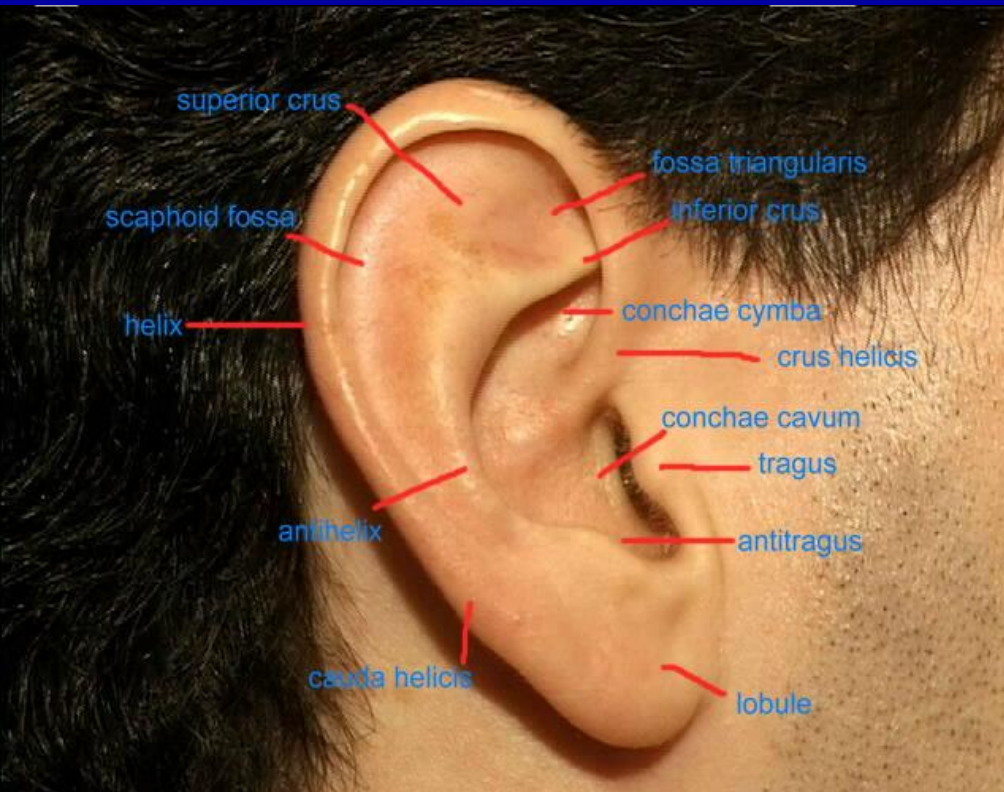
Diseases of the external  
and middle ear.

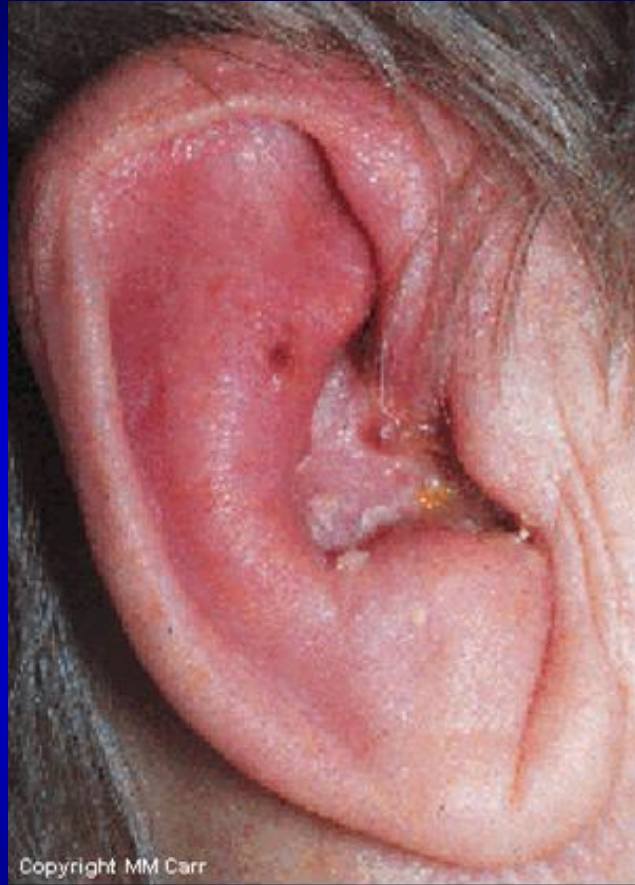Asist.univ.Chiaburu-Chiosa  
Doina

# EXTERNAL EAR

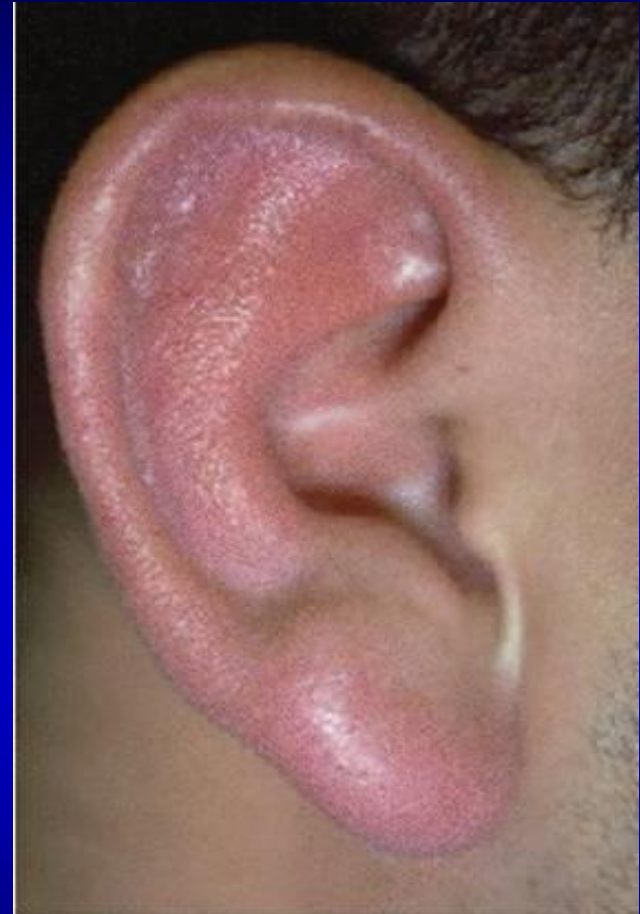

# THE AURICLE





Perichondritis

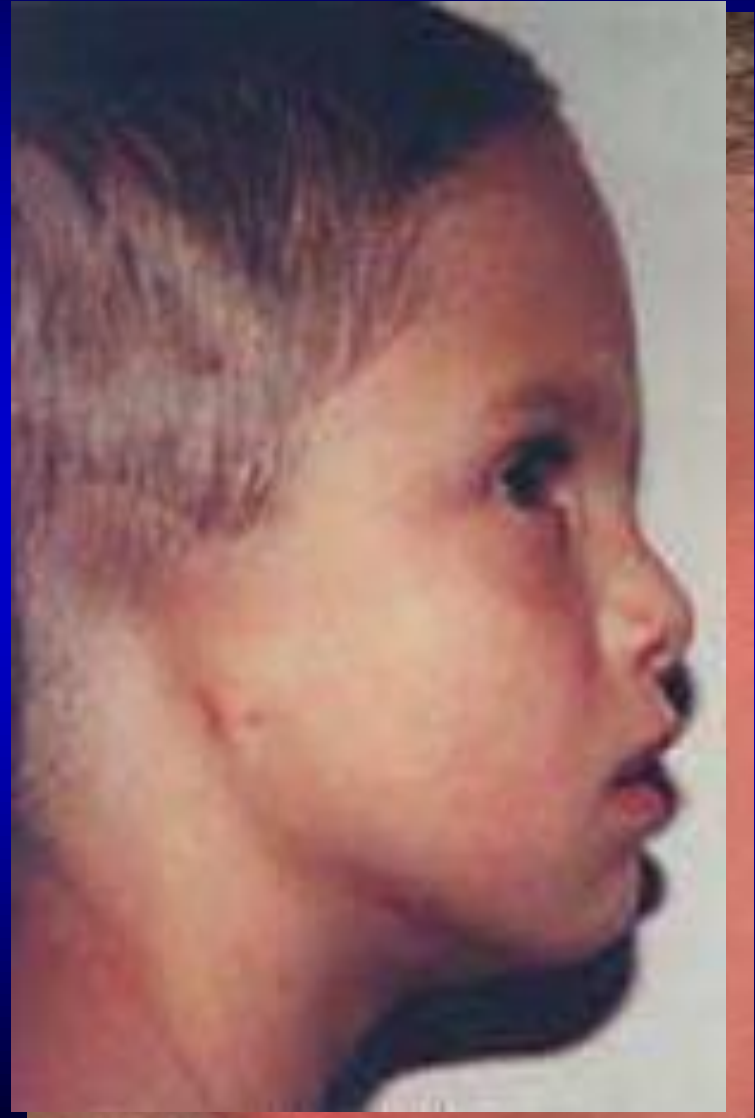

Erysipelas

# DISEASES OF THE EXTERNAL EAR

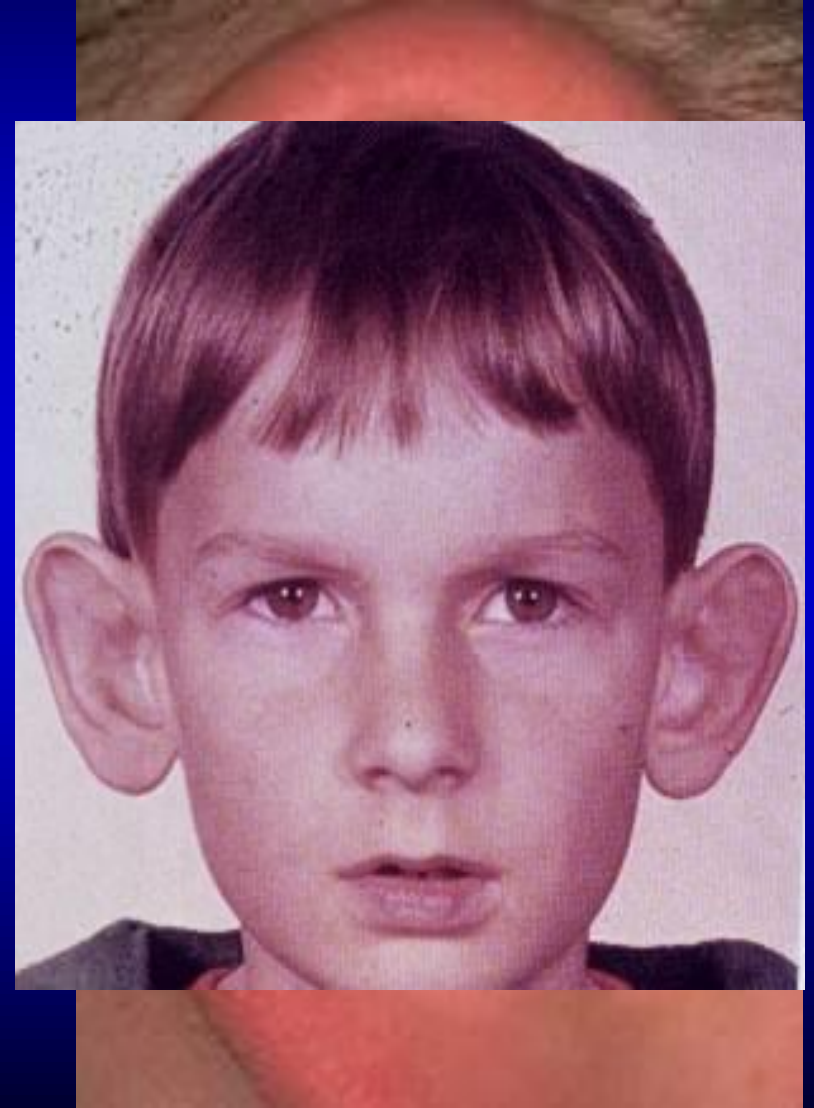
# CONGENITAL MALFORMATIONS

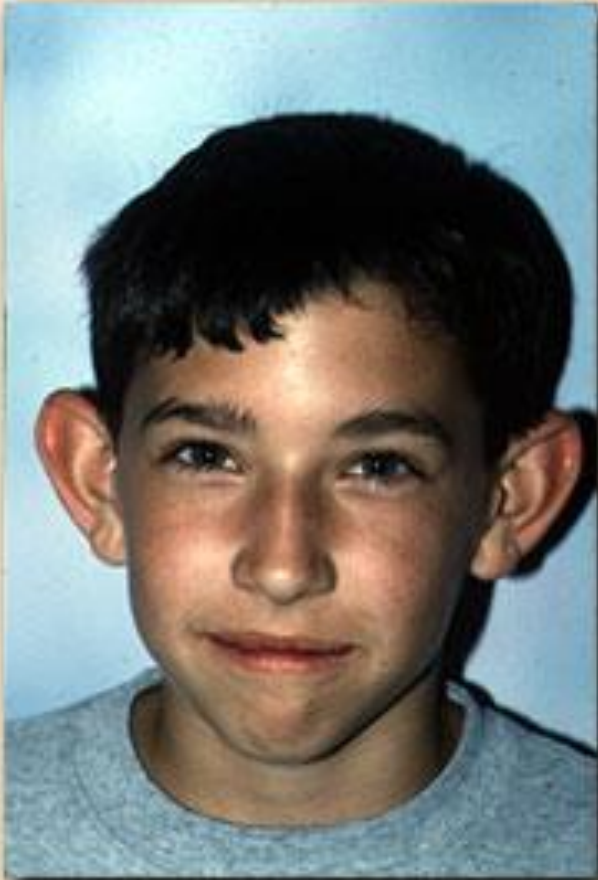- Anotia & microtia
- Accessory auricle
- Preauricular sinus
- Protruding ear



# CONGENITAL MALFORMATIONS

- Anotia & microtia
- Accessory auricle
- Preauricular sinus
- Protruding ear

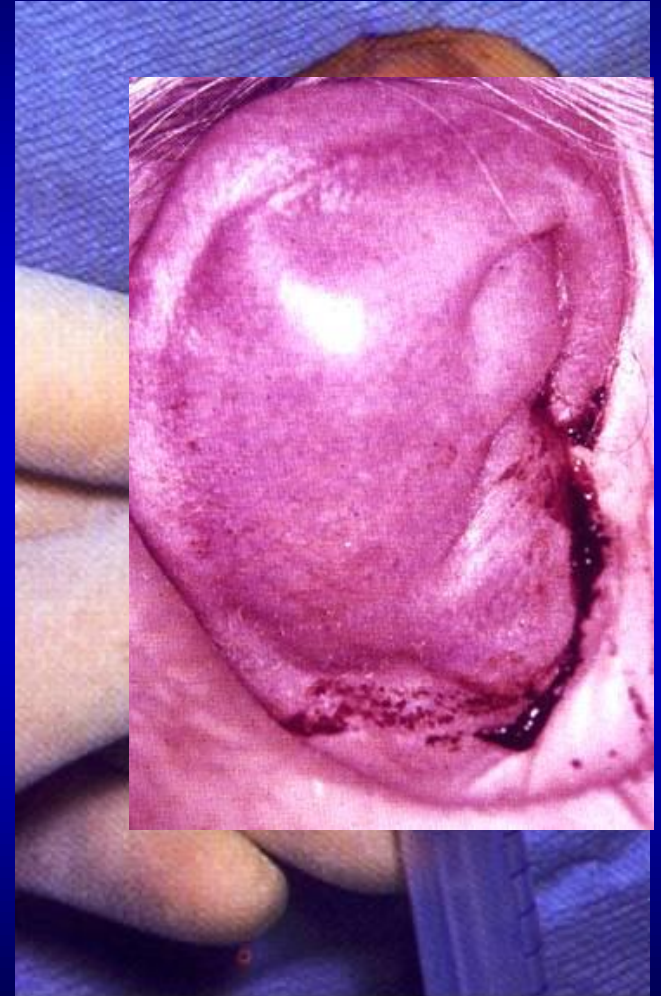




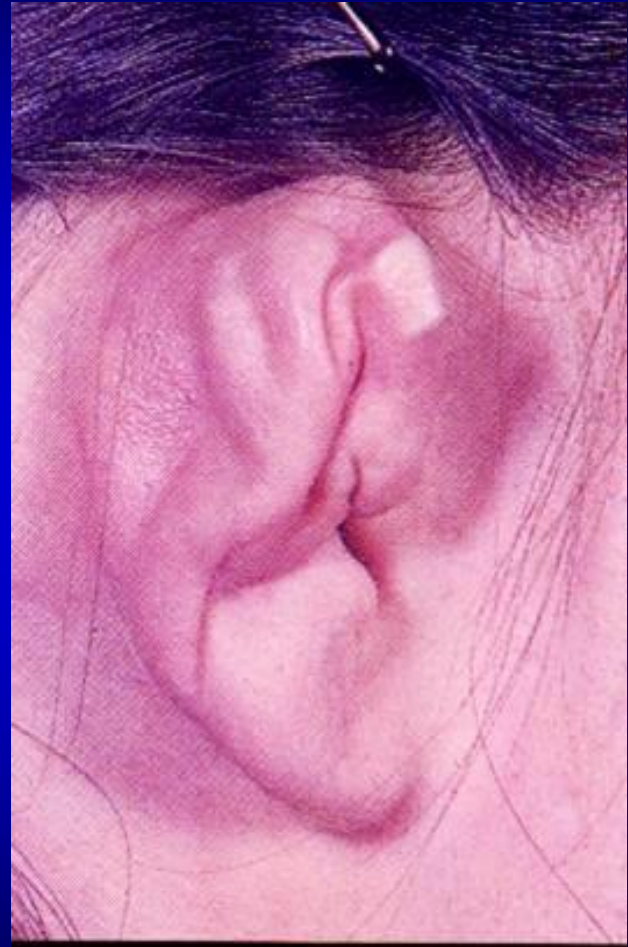
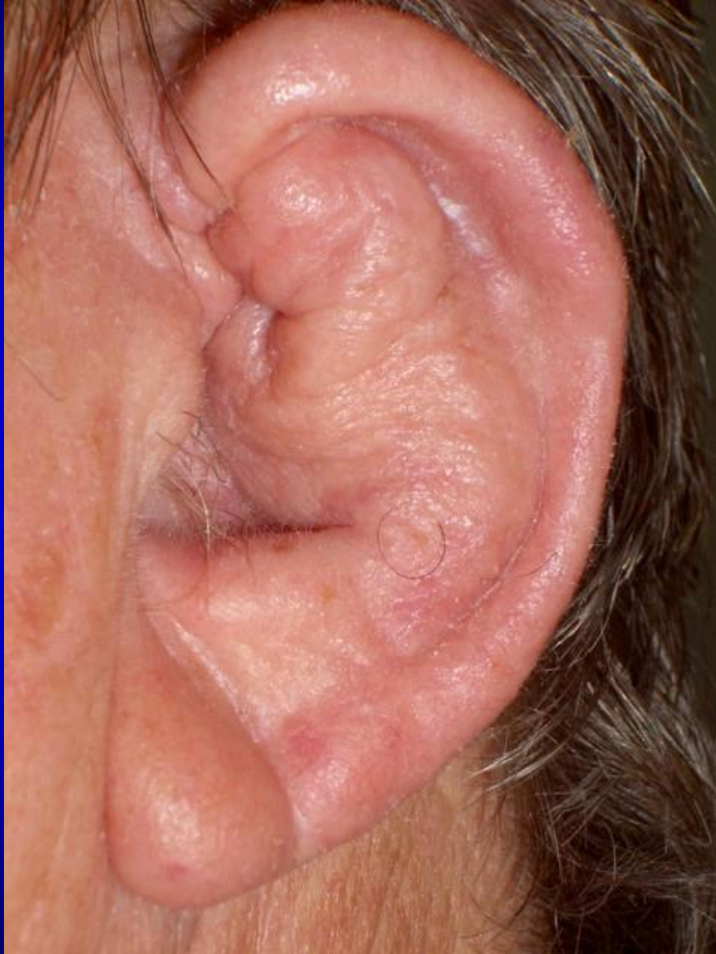
# TRAUMA TO THE AURICLE

- Lacerations
- Hematoma auris



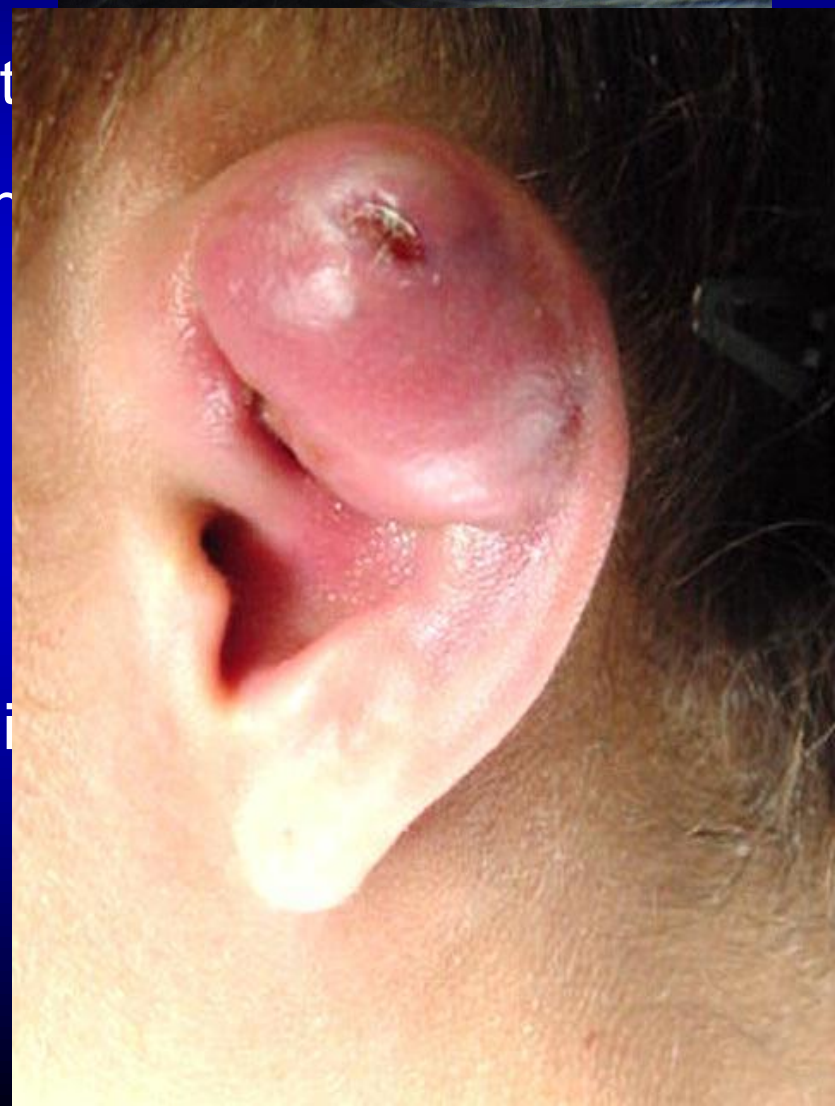# Complication



Cauliflower ear

# PERICHONDritis OF THE PINNA

- Usually follow trauma (hematoma, auris, surgical, frostbite, burn, otitis externa)
- Commonly caused by *Pseudomonas*
- Fever, pain, redness and swelling
- Treatment is by antibiotics

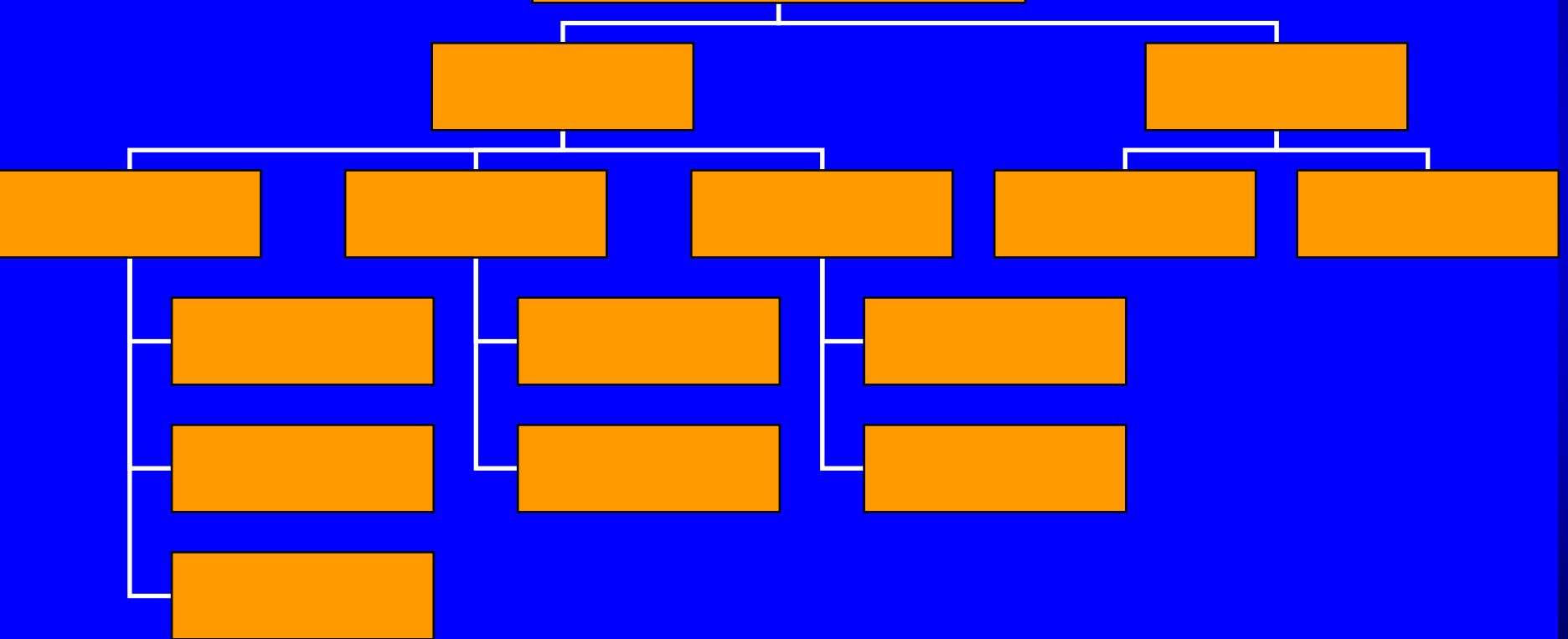


# OTITIS EXTERNA

# DEFINITION

- An acute or chronic infection of the whole or a part of the skin of the external ear canal

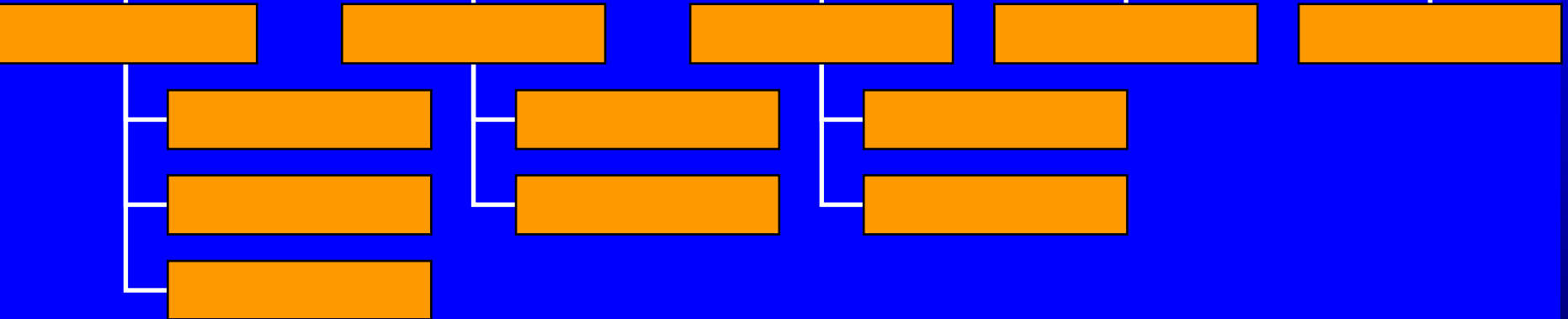
# CAUSES OF OTITIS EXTERNA



CAUSES OF OTITIS EXTERNA

INFECTIVE

REACTIVE



CAUSES OF OTITIS EXTERNA

INFECTIVE

REACTIVE

Bacterial

Fungal

Viral

[Empty box]

[Empty box]

[Empty box]

[Empty box]

[Empty box]

[Empty box]

[Empty box]

[Empty box]

[Empty box]



CAUSES OF OTITIS EXTERNA

INFECTIVE

REACTIVE

Bacterial

Fungal

Viral

Eczematous

Seborrheic

[Empty box]

[Empty box]

[Empty box]

[Empty box]

[Empty box]

[Empty box]

[Empty box]

CAUSES OF OTITIS EXTERNA

INFECTIVE

REACTIVE

Bacterial

Fungal

Viral

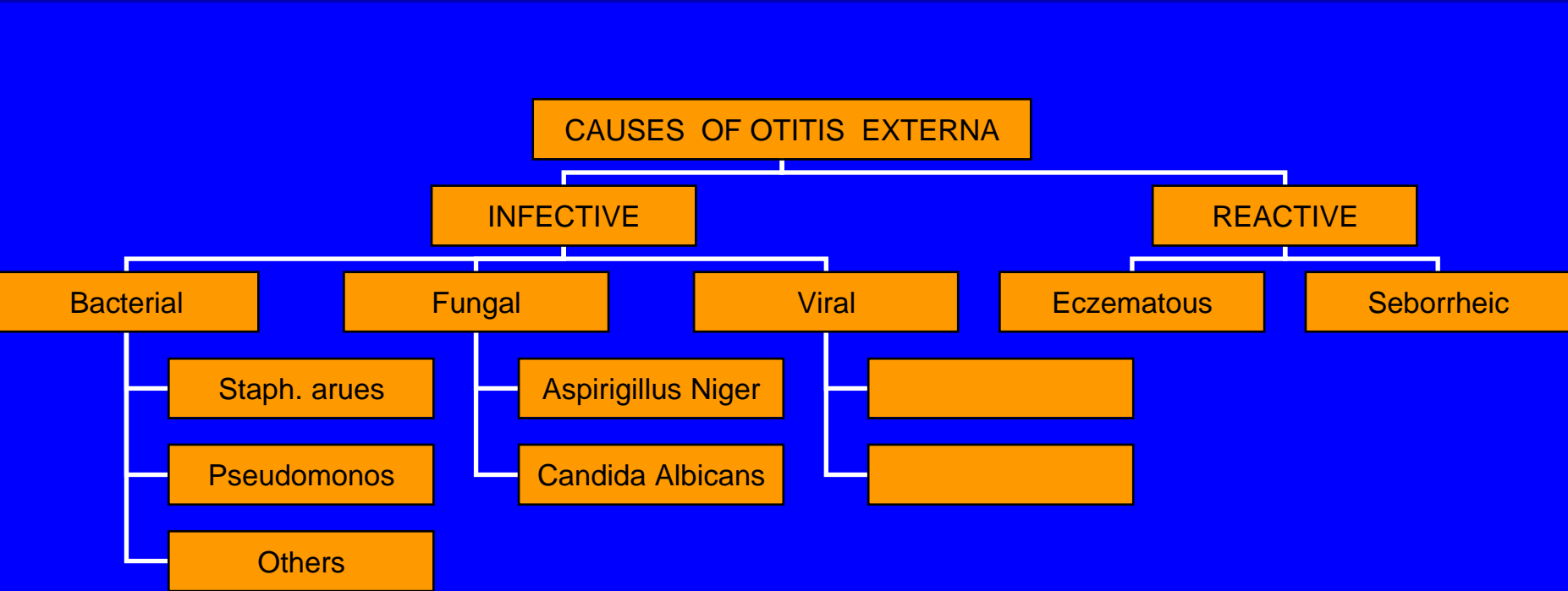
Eczematous

Seborrheic

Staph. aureus

Pseudomonas

Others



# CAUSES OF OTITIS EXTERNA

## INFECTIVE

## REACTIVE

### Bacterial

### Fungal

### Viral

### Eczematous

### Seborrheic

Staph. aureus

Pseudomonas

Others

Aspergillus Niger

Candida Albicans

Herpes zoster

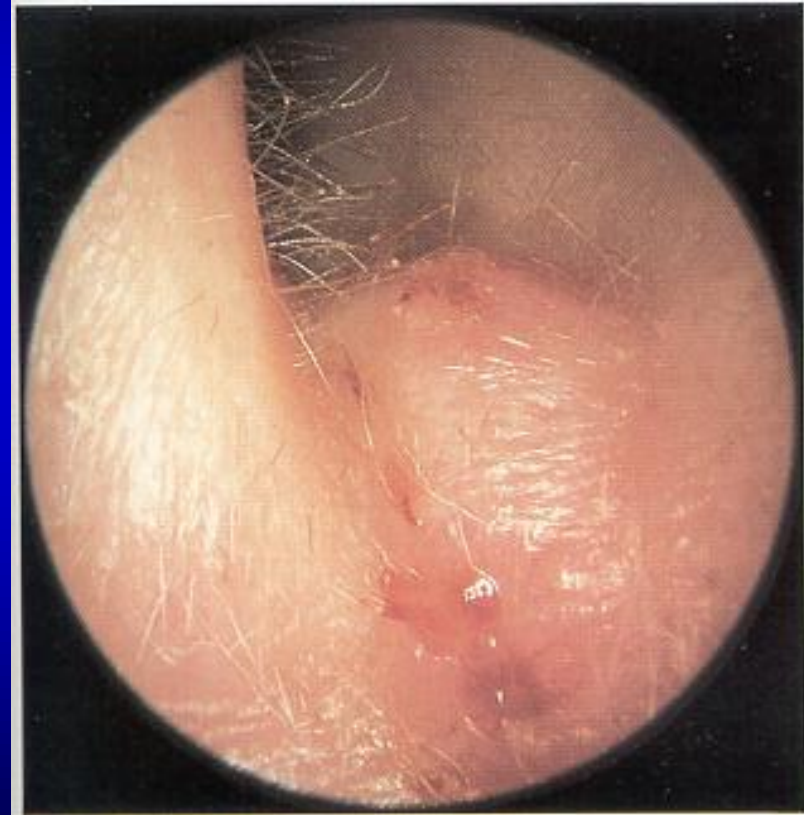Others

# CLINICAL FEATURES OF OTITIS EXTERNA

- Itching
- Pain
- Tenderness and swelling
- Otorrhea
- Deafness
- Changes in the lumen and skin of EAM

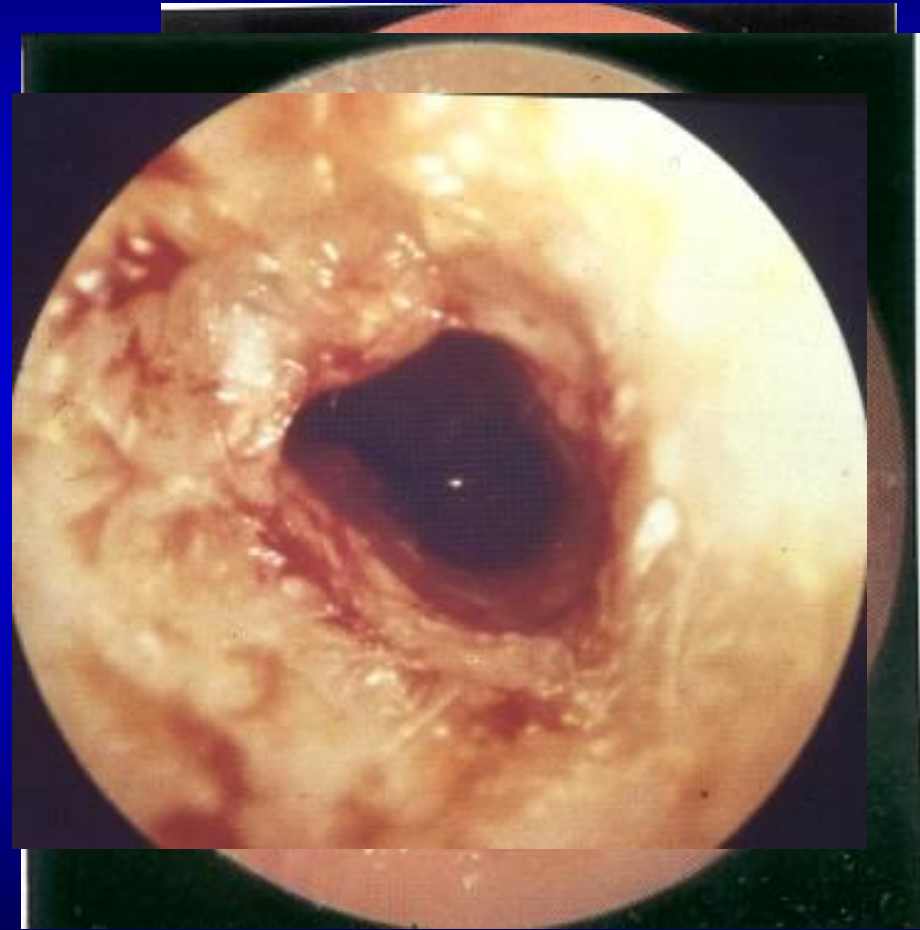
# CLINICAL TYPES OF OTITIS EXTERNA

- Localize O.E ( furuncle)



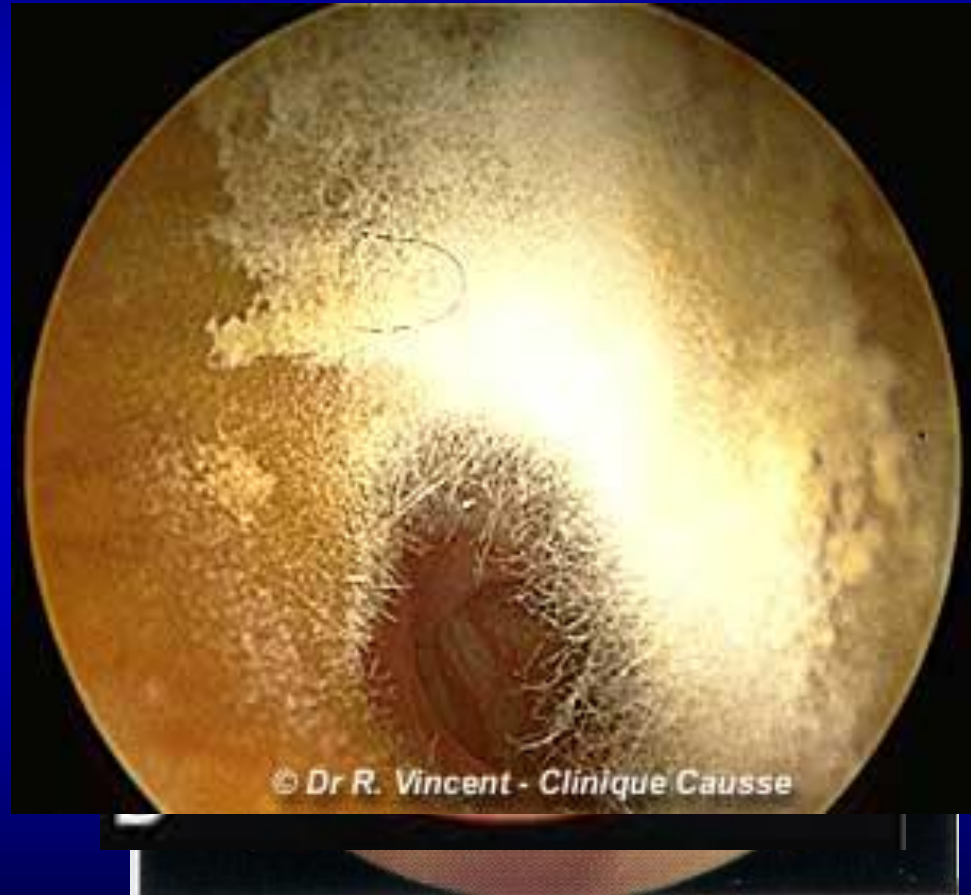
# CLINICAL TYPES OF OTITIS EXTERNA

- Localize O.E  
(furuncle)
- Diffuse infective O.E.



# CLINICAL TYPES OF OTITIS EXTERNA

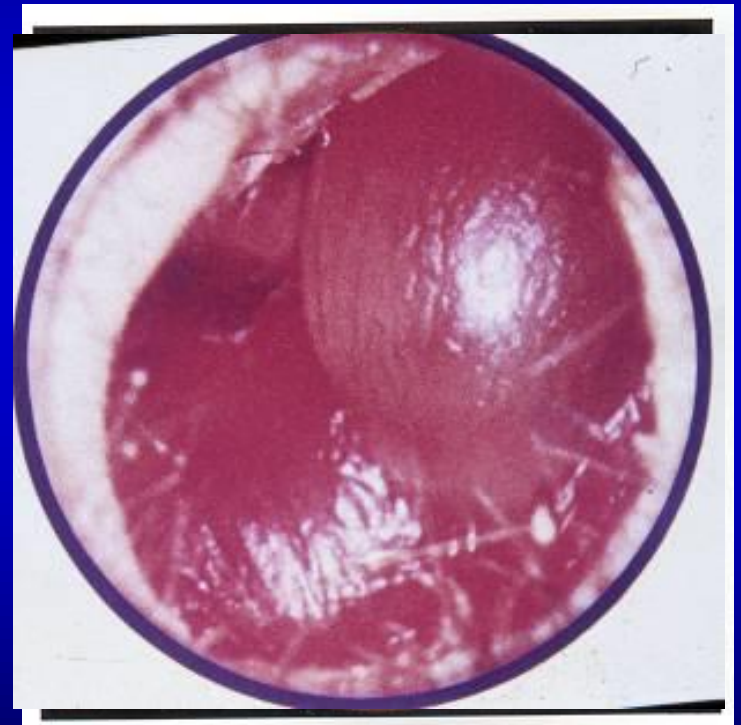
- Localize O.E
- (furuncle)
- Diffuse infective O.E.
- Otomycosis





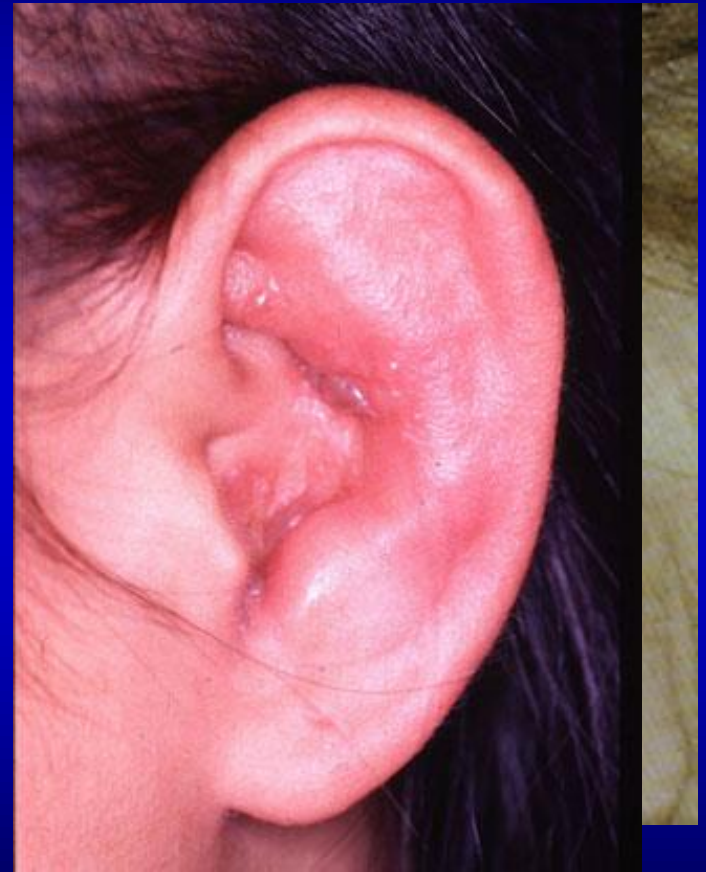# CLINICAL TYPES OF OTITIS EXTERNA

- Localize O.E (furuncle)
- Diffuse infective O.E.
- Otomycosis
- Bullous myringitis



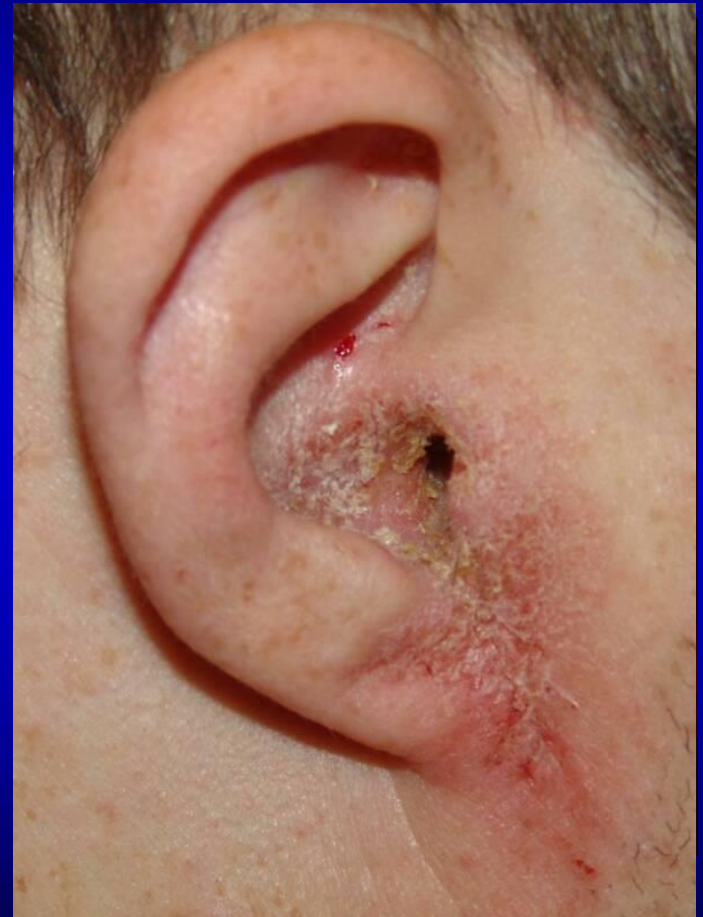# CLINICAL TYPES OF OTITIS EXTERNA

- Localize O.E  
(furuncle)
- Diffuse infective O.E.
- Otomycosis
- Bullous myringitis
- Herpetic O.E.



# CLINICAL TYPES OF OTITIS EXTERNA

- Localize O.E  
(furuncle)
- Diffuse infective O.E.
- Otomycosis
- Bullous myringitis
- Herpetic O.E
- Eczematous and seborrheic O.E.



# CLINICAL TYPES OF OTITIS EXTERNA

- Localize O.E ( furuncle)
- Diffuse infective O.E.
- Otomycosis
- Bullous myringitis
- Herpetic O.E
- Eczematous and seborrheic O.E.
- “Malignant” otitis externa

# MANAGEMENT OF OTITIS EXTERNA

- Swab for culture and sensitivity
- Ear toilet
- Keep the ear dry
- Local medications
- Systemic medications
- Surgery may be required in chronic cases

